

Pentosan Polysulfate Sodium (Elmiron) Position Statement

March 2022

Pentosan Polysulfate sodium (PPS), also known as Elmiron, is an oral medication prescribed for the treatment of interstitial cystitis (IC). PPS has been used to treat IC since 1996.

A dose-related progressive retinal maculopathy is associated with the use of PPS. The retinal changes from PPS include macular edema, choroidal neovascularization and retinal pigment epithelial hyperpigmentation followed by atrophy. Severe vision loss is associated with late PPS maculopathy.

PPS maculopathy was first described in 2018.[1] The prevalence of maculopathy is directly proportional to cumulative dose, with one study showing the prevalence risk for retinopathy increasing from 12.7% for 500 to 999 grams, to as high as 41.7% for greater than 1,500 grams.[2] The cumulative dose for patients taking PPS is approximately 100 grams per year, thereby leading to potential retinal damage within three to five years.

We recommend that PPS prescribers exhaust alternative treatments for IC prior to prescribing PPS. All patients prescribed PPS should be notified of the significant risk of retinal toxicity by their prescribing physician. All patients prescribed PPS should be concomitantly referred to an ophthalmologist experienced in the identification of this disease entity for eye screening. If toxicity is detected, PPS should be discontinued. PPS retinal toxicity is permanent, irreversible, and progressive.

PPS baseline and annual follow up screening protocol

Dilated fundus examination or true colour or colour reconstructed retinal photographs.

Retinal imaging of the macula

Required:

1. *Fundus autofluorescence (FAF)*
2. *Optical coherence tomography (OCT) (enface and cross-section)*

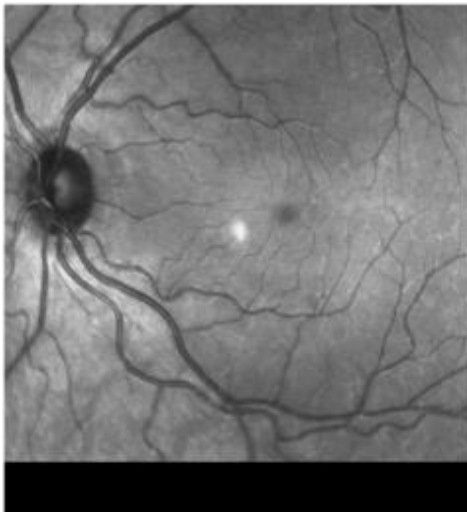
Where available:

1. *Near infrared autofluorescence (NIR-AF)*

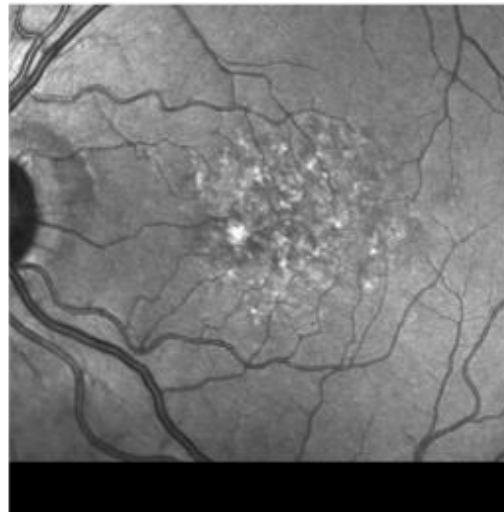
If a patient has macular pathology at baseline or first exam, then a discussion between the ophthalmologist and the prescribing physician should take place prior to starting PPS. If PPS toxicity is suspected, then PPS should be discontinued.

Clinical example of PPS toxicity developing in a young female after eight years of continuous use.

In 2013, at the age of 33, this patient's retinas were normal without evidence of macular changes. Eight years later, they showed marked retinal damage with reduced vision in both eyes. Photos supplied.



Pre-toxicity



Post-toxicity

References

[1] Pearce WA, Chen R, Jain N. Pigmentary Maculopathy Associated with Chronic Exposure to Pentosan Polysulfate Sodium. *Ophthalmology*. 2018;125(11):1793-1802. doi:10.1016/j.ophtha.2018.04.026

[2] Vora RA, Patel AP, Melles R. Prevalence of Maculopathy Associated with Long-Term Pentosan Polysulfate Therapy. *Ophthalmology*. 2020;0(0). doi:10.1016/j.ophtha.2020.01.017